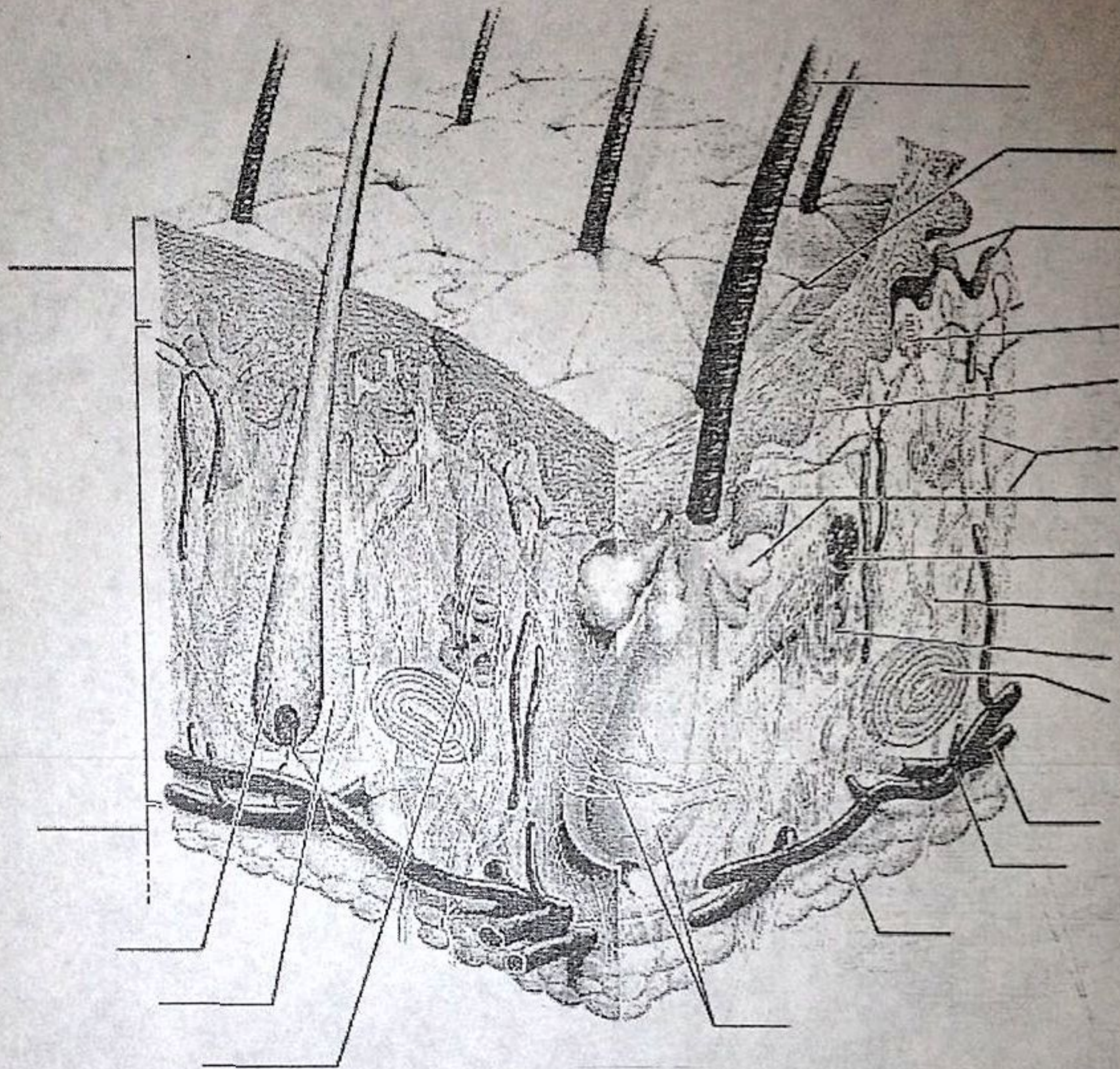


Match up the correct integumentary structure with its label below.



Copyright © 2004 Pearson Education, Inc., publishing as Benjamin Cummings.

- ___ Dermal blood vessels
- ___ Dermal papillae
- ___ Dermis
- ___ Eccrine sweat gland
- ___ Epidermis
- ___ Hair follicle

- ___ Dermal blood vessels
- ___ Dermal papillae
- ___ Dermis
- ___ Dermal blood vessels
- ___ Epidermis

- ___ Hair root
- ___ Hair shaft
- ___ Hypodermis
- ___ Meissner's corpuscle
- ___ Pacinian corpuscle
- ___ Sebaceous gland